

Ashamuddin NA¹, Tan JT², Tan EL², Mot YY³, Mohd Yusoff N^{1,2}

¹Department of Clinical Medicine, Advanced Medical and Dental Institute, Universiti Sains Malaysia, 13200 Kepala Batas, Malaysia

²Sunway Medical Center Penang, 3106, Lebuh Tenggiri 2, Pusat Bandar Seberang Jaya, 13700 Perai, Pulau Pinang, Malaysia

³Asian Institute of Medical Science and Technology, Batu 3½, Bukit Air Nasi, Jalan Bedong – Semeling, 18100, Bedong, Kedah, Malaysia

Received 21 July 2025
Revised 17 September 2025
Accepted 28 January 2026
Published Online 1 March 2026

*Corresponding author
Noor Aqilah Ashamuddin
nooraqilahasham@student.usm.my

Severe Thrombocytosis in a Patient with Pulmonary Tuberculosis: A Case Report

Abstract – Platelets are key players in the immunopathology of pulmonary tuberculosis (TB), and thrombocytosis is a rare complication of the disease. Thrombocytosis is defined as platelet counts exceeding $450 \times 10^9/L$. In TB, thrombocytosis is associated with other hematological changes and an increased risk of venous thromboembolism (VTE). An 80-year-old man presented with a chronic cough for 2 weeks, without fever, weight loss, night sweats, family history of blood dyscrasia, or prior thrombotic events. Full blood count (FBC) showed leukocytosis with high white blood cells (WBC) ($22.63 \times 10^3/uL$), neutrophils ($19.49 \times 10^3/uL$), and platelets ($1808 \times 10^9/L$). Peripheral blood film (PBF) showed leukocytosis with neutrophilia, monocytosis, and basophilia. Red blood cells (RBC) showed microcytic hypochromic anemia, and platelets were grossly increased with circulating megakaryocyte fragments. Essential thrombocytosis was suspected based on persistent thrombocytosis (normal range $150\text{--}450 \times 10^9/L$) for 1 week during admission; however, JAK2 mutation analysis was negative. Suspicion of pulmonary TB due to cough was confirmed via Gene-Xpert MTB/RIF sputum test (PCR). Subsequently, anti-tuberculosis therapy was initiated, and the patient responded well. The patient's platelet count was monitored, but the patient was not on any VTE prophylaxis. Platelets may directly sense *Mycobacterium tuberculosis* (*M. tuberculosis*). As a rapid innate immune response, platelets become activated and granulated, releasing pro-inflammatory cytokines. Platelets then undergo structural changes and upregulate platelet-activated gene transcripts. Tissue damage in TB results from platelet interactions with other leukocytes, which produce matrix metalloproteinases (MMPs) and cytokines such as Interleukin-10 (IL-10) that inhibit the host immune response. Conclusion: There should be a high index of suspicion for TB infection in patients presenting with respiratory symptoms and severe thrombocytosis, especially in older patients. Antiplatelet therapy may be considered alongside the standard antitubercular drug regimen as a potential host-directed therapy to improve outcomes and prevent VTE complications in patients with pulmonary TB and severe thrombocytosis.

Keywords: Thrombocytosis, Tuberculosis, Pulmonary, Platelet, Immunology

1 INTRODUCTION

Tuberculosis (TB) is the second leading infectious disease after COVID-19, surpassing Human Immunodeficiency Virus (HIV) and Acquired Immunodeficiency Syndrome (AIDS) worldwide. The World Health Organization (WHO) estimates that 1.3 million people died from TB in 2025 and that 10.7 million were infected with TB (5.8 million men, 3.7 million women, and 1.2 million children), even though TB is a curable and preventable disease. Globally, the disease burden is about US \$13 billion annually for prevention, diagnosis, treatment, and care. About a quarter of the global population is estimated to have been infected with

TB, with variable clinical manifestations. Malaysia had a population of 34 million in 2022. However, TB data for 2022 versus 2015 show a dramatic rise of 80% in TB deaths and a 26% increase in TB incidence. In 2024, the incidence and mortality rates of TB in Malaysia are 76.88 and 7.58 per 100000 population (Malaysia Health Facts 2025). Smoking is the highest risk factor associated with TB, followed by alcohol use disorder, undernourishment, diabetes, and, lastly, HIV. The TB disease burden on Malaysia's economy in 2022 is estimated at US\$16 million, with a rise of 2.3% compared to the previous year (1). TB is caused by *M. tuberculosis*, a human pathogen.

Humans are the only known reservoir of *M. tuberculosis*, although animals can be infected and zoonotic transmission can occur. TB is primarily transmitted through airborne droplets generated by coughing, sneezing, or speaking. TB commonly causes pulmonary tuberculosis, but it can also infect other organs (extrapulmonary TB). *M. tuberculosis* is an aerobic, non-spore-forming, non-motile bacillus with a high lipid content in the cell wall, which makes the bacilli acid-fast and likely contributes to immunomodulation and virulence. Its intracellular localization leads to subacute, progressive disease manifestations that can also remain dormant within infected cells.

2 CASE REPORT

An 80-year-old man was admitted to a tertiary private hospital and presented with a chronic cough for two (2) weeks, without fever, weight loss, night sweats, family history of blood dyscrasia, or any thrombotic event. Full blood count (FBC) shows leukocytosis (white blood cells (WBC) count: $22.63 \times 10^3/\mu\text{L}$) with a predominant neutrophils (neutrophils count was $19.49 \times 10^3/\mu\text{L}$, and remarkable thrombocytosis (platelet count was $1858 \times 10^9/\text{L}$), Mean Platelet Volume (MPV) is 8.4/fL (normal 7.5 – 12/fL), Platelet Distribution Width (PDW) is 8.6/fL (normal 8.1 – 25.0/fL). Peripheral blood film (PBF) shows absolute leukocytosis with neutrophils, monocytosis, and basophilia. Left shift with band forms, myelocytes, and some dysplastic neutrophils. Red blood cells are microcytic and hypochromic, with acanthocytes and cigar cells observed. Severe thrombocytosis with circulating megakaryocyte fragments and platelet anisocytosis with small, large, and giant platelets. The differential diagnosis was essential thrombocytosis (ET) and severe infection. Iron study and liver function test were normal. Essential thrombocytosis was suspected due to persistent thrombocytosis (normal range $150\text{--}450 \times 10^9/\text{L}$) for 1 week during admission but was ruled out as mutation analysis for JAK2 was negative. Suspicion of pulmonary TB due to cough was confirmed via Gene-Xpert MTB/RIF sputum test (PCR). Computed tomography (CT) chest scan demonstrates features consistent with infection and shows generalized bronchiectasis in both lungs, calcification, cavitation, and nodules in all lobes except the right upper lobe. Subsequently, anti-tuberculosis therapy was initiated, to which the patient responded well. The patient's platelet count was closely monitored, and levels continued to decline without any VTE prophylaxis. The

recovery was uncomplicated, and the thrombocytosis resolved.

3 DISCUSSION

Etiologies of secondary thrombocytosis can be easily remembered as “5 I’s” - inflammation, ischemia, infection, infarction, and iron deficiency (2). Thrombocytosis is defined as a platelet count greater than $450 \times 10^9/\text{L}$, and extreme thrombocytosis (platelet count $\geq 1000 \times 10^9/\text{L}$) is uncommon and may indicate more than a reactive phenomenon (3). In a comparative cross-sectional study of 164 newly diagnosed tuberculosis patients in Ethiopia, 11.6% had thrombocytosis and 9.8% had thrombocytopenia, based on WHO-defined platelet count cut-offs ($>450 \times 10^3/\mu\text{L}$ and $<150 \times 10^3/\mu\text{L}$) using automated complete blood count analysis (4). Thrombocytosis in TB will demonstrate significant correlation with Mean Platelet Volume (MPV) (5,6) as well as platelet count, and platelet distribution width (5). TB also causes thrombocytopenia, and some studies suggest that the role of platelets in the immunology of tuberculosis is not fully understood (7).

M. tuberculosis are phagocytosed by macrophages after inhalation, which activate and recruit other immune cells like neutrophils, monocytes, natural killer cells and lymphocytes, particularly CD4+ T helper cells (8,9). Extravasation of platelet and its biogenesis as well as presence of megakaryocytes that escalate the platelet generation in response to specific stimuli, may explain why platelets are present in the site of TB. This patient shows atypical fragments of megakaryocytes in his PBF. It is proposed that platelet may sense *M. tuberculosis* via Toll Like Receptor (TLR) 2 and TLR 4 thus activated and granulate to release proinflammatory cytokines like IL-10 but decreased secretion of Interleukin-1 β (IL-1 β), Interleukin-6 (IL-6) and Tumour Necrosis Factor α (TNF α) (8). Platelet-associated gene transcripts are upregulated with changes in its structure and function acting as a rapid innate immune response is seen in Tuberculosis patients (8). In a cohort study of newly diagnosed drug sensitive smear patients, platelet drive a pro-inflammatory condition, tissue degrading phenotype demonstrated by increased Platelet Factor 4 (PF4) on day 14 compared to day 60 of treatment, showing correlation of PF4 with the disease progression (9). In the same study, other markers such as matrix metalloproteinase-1 (MMP-1), platelet derived growth factor-BB (PDGF-BB), and RANTES were also increased. Platelet also encourage monocytes production of

IL-1 β and Interleukin-10 (IL-10) in which the later inhibit both innate and adaptive pathway, inhibit phagosome in the monocyte, limiting the induction of T-helper cell type 1 lymphocytes and thus support *M. tuberculosis* survival in the lungs (10). Interleukin-6 (IL-6) promotes megakaryopoiesis in TB resulting in thrombocytosis in TB patients (11,12).

There are significant hematological changes that occur in association in TB and the parameters are useful for predicting the severity, making the diagnosis and management along with monitoring of the disease progression (13, 14). Red blood cells (RBC) changes in TB includes low haemoglobin, RBC count, hematocrit and TB patient are usually anaemic (13,15). For RBC morphologically, 52% patients are microcytic hypochromic, 40% patients are normocytic normochromic and 8% are macrocytic hypochromic (13). Increased TNF α , interferon- γ (IFN- γ), and IL-6 in TB cause decreased erythropoiesis formation, leading to bone marrow suppression, along with poor iron transport and chronic inflammation, which could be the cause of anaemia (13,15). Leukocytosis and neutrophilia are manifestations of white blood cell (WBC) changes in TB. About 40.9% of patients had leukocytosis, but there was a low positive correlation between reactive thrombocytosis and WBC in TB (16). Monocyte and basophil counts are significantly higher in the TB control group (11). C-reactive protein (CRP) is synthesized in the liver, influenced by IL-6, and rapidly responds to infection, inflammation, trauma, tissue necrosis, and surgery (14). CRP is positive in 86.7% and negative in 13.3% of TB patients associated with thrombocytosis (14). Erythrocyte sedimentation rate (ESR) is not a specific test, as it is elevated in many diseases, and it is reported to be 98% positive in TB patients in India (16). Both markers of acute-phase reactants (ESR, CRP) are elevated in reactive thrombocytosis and may be useful indicators of TB disease, as they are easily available in many developing countries (17). All the common hematological abnormalities in pulmonary TB are reversible (18).

TB is associated with a hypercoagulable state, hematological changes, and chronic inflammation, leading to uncommon venous thromboembolism (VTE) complications, including deep vein thrombosis (DVT) and pulmonary emboli (PE) (19). Kumarihamy reported a rare case of DVT in severe pulmonary TB, with superadded infections during treatment, that resulted in mortality (19) McKinnon also reported a case series of three

patients with pulmonary TB who were on treatment and had complications related to pulmonary embolism (20). Stasis, endothelial lesions that release pro-coagulants such as kallikrein and activate the complement cascade, as well as lymph node enlargement causing direct venous compression are other possible mechanisms that cause the complication (20). Decreased antithrombin III and protein C, along with elevated factor VIII, plasminogen activator inhibitor I, and fibrinogen, as well as increased platelet aggregation and reactive thrombocytosis, also contribute to the hypercoagulable state. Some antitubercular drugs increase the risk of VTE. As such, Rifampicin and Isoniazid, with the former being a potent inducer of cytochrome P450 (CYP) enzymes and transporters, can significantly reduce the efficacy of anticoagulants and complicate the achievement of the target INR value in patients with VTE. It's important for clinicians to maintain a high index of suspicion for VTE complications among TB patients. Few studies have suggested antiplatelet therapy as an adjunct to anti-TB drugs. Kirwan proposed that antiplatelet agents, such as nonsteroidal anti-inflammatory drugs (NSAIDs) and P2Y12 inhibitors (such as Ticagrelor and Clopidogrel), may inhibit platelets and exhibit direct antimycobacterial properties, thus preventing further collateral tissue damage in TB (8). Lee et al also conclude that better overall survival and lower 12 months mortality in pulmonary TB patients who received anti-tubercular and antiplatelet drugs (21) Aspirin administration in TB patients has also demonstrated irreversible inhibition of both cyclooxygenase (COX) enzymes, thereby preventing thromboxane A2 generation, which is a potent platelet activator (20) Aspirin provides anti-thrombotic effect at low dose and anti-inflammatory effect at higher dose (8).

CONCLUSION

This is an extremely rare case of pulmonary TB with severe thrombocytosis in an elderly patient. Clinicians should consider TB in the differential diagnosis of respiratory illness and thrombocytosis, given its high endemicity in our region, before pursuing other aggressive diagnostic tests. Adjunctive antiplatelet therapy may hold promise as a host-directed intervention for TB but requires further clinical validation on a case-by-case basis. Earlier literature has shown that platelets are key players in the immunopathology of TB, warranting further efforts to develop interventions targeting inflammatory

responses in TB. Targeting platelets with antiplatelet agents is being considered as a potential host-directed therapy to limit tissue

damage and improve treatment outcomes among TB patients.

Table I. Full Blood Count during admission

Parameter	Result	Normal value
White blood cell (WBC) x 10 ³ /uL	22.63	4.00-10.00
Red blood cell (RBC) x 10 ¹² /uL	4.94	3.86-5.62
Haemoglobin (Hb) / g/dL	12.20	11.80-16.90
Hematocrit (HCT) / %	36.90	35.70-48.90
Mean corpuscular volume (MCV) / fL	74.70	80.60-95.50
Mean corpuscular haemoglobin (MCH) / pg	24.70	26.90-32.30
Mean corpuscular haemoglobin concentration (MCHC) / g/dL	33.10	31.90-35.30
Platelet x 10 ⁹ /L	1868.00	142-350
Red cell distribution width - standard deviation (RDW-SD) / fL	45.80	37.50-48.10
Red cell distribution width - coefficient of variant (RDW-CV) / %	17.90	12.00-14.80
Platelet distribution width (PDW) / fL	8.60	10.10-16.10
Mean platelet volume (MPV) / fL	8.40	9.30-12.10
Nucleated red blood cells (NRBC) / %	0.00	0.00
Neutrophils / 10 ³ /uL	19.49	4.00-10.00
Lymphocyte / 10 ³ /uL	1.26	2.00-7.00
Monocytes / 10 ³ /uL	1.71	1.00-3.00
Eosinophils / 10 ³ /uL	0.06	0.20-1.00
Basophils / 10 ³ /uL	0.11	0.00-0.10
Immature granulocytes (IG) / %	1.00	0.00-0.60
Reticulocytes (Ret) / %	1.58	0.43-1.36
Immature reticulocytes fragments (IRF) / %	12.10	2.00-16.10
Low fluorescence ratio (LFR) / %	87.90	82.47-97.99
Medium fluorescence ratio (MFR) / %	10.00	2.00-14.03
Highly fluorescence reticulocytes (HFR) / %	2.10	0.00-2.50
Reticulocytes Haemoglobin Equivalent (Ret-He) / pg	27.40	

(Normal range source: Angeli Ambayya et. al., 2014. Hematologic Reference Intervals in a multiethnic population and reference range of Sysmex XE-2100)

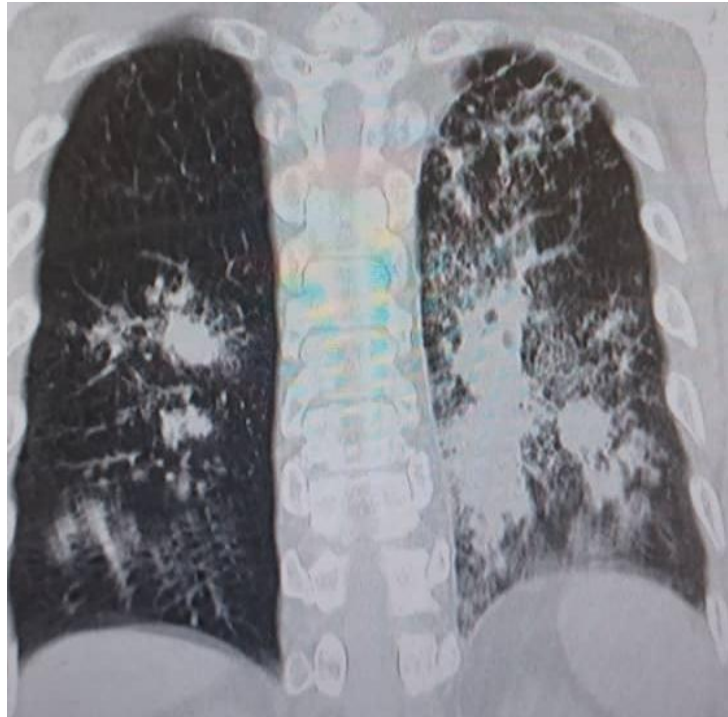


Figure 1. Computed tomographic (CT) chest scan (coronal view) during admission.

ACKNOWLEDGEMENTS

We would like to thank the Director-General of Health, Ministry of Health Malaysia for permission to publish this paper. We would also like to extend our appreciation to Advanced Medical and Dental Institute (AMDI), Universiti Sains Malaysia, Pulau Pinang, Sunway Medical Centre Penang and the patient who contributed to this study.

AUTHOR CONTRIBUTIONS

Ashamuddin NA: Conceptualization, Investigation, Data Curation, Writing – Original Draft.

Tan JT, Tan EL, Mot YY: Formal Analysis, Statistical analysis, Validation, Visualization.

Mohd Yusoff N: Supervision, Project Administration, Writing – Review & Editing

AUTHORSHIP CLARIFICATION

Ashamuddin NA led in clinical design, patient data collection, and manuscript drafting, affiliated with Universiti Sains Malaysia. Tan JT & Tan EL handled hematological data analysis and diagnostic imaging interpretation at Sunway

Medical Center. Mot YY offered methodological guidance and coordination at Asian Institute of Medical Science and Technology. Mohd Yusoff N supervised, managed, and validated the project at Universiti Sains Malaysia and Sunway Medical Center Penang.

ETHICS APPROVAL AND CONSENT TO PARTICIPATE

Ethics approval for this case report was obtained from the relevant institutional committees. Permission to publish this clinical data was granted by the Director-General of Health, Ministry of Health Malaysia. The study was conducted in accordance with the Declaration of Helsinki.

CONSENT FOR PUBLICATION

Approval and permission to publish this clinical study were granted by the Director-General of Health, Ministry of Health Malaysia, with additional acknowledgment from the Advanced Medical and Dental Institute (AMDI), Universiti Sains Malaysia, and Sunway Medical Centre Penang.

CONFLICTS OF INTEREST

The authors declare that they have no competing interests.

REFERENCES

- [1] World Health Organization: WHO & World Health Organization: WHO. (2023, November 7). Tuberculosis. <https://www.who.int/news-room/fact-sheets/detail/tuberculosis>
- [2] Rokkam VR, Kotagiri R. Secondary Thrombocytosis [Internet]. PubMed. Treasure Island (FL): StatPearls Publishing; 2020. Available from: <https://www.ncbi.nlm.nih.gov/books/NBK560810/>
- [3] Zulkafli Z, Janaveloo T, Ab Rahman WSW, Hassan MN, Abdullah WZ. Extreme Thrombocytosis in a Child: Laboratory Approaches and Diagnostic Challenges. *Oman Medical Journal*. 2019 Jul 20;34(4):336–40.
- [4] Angesom Gebreweld, Temesgen Fiseha, Kebede E, Tamir Z, Gebremariam B, Fikadu Miruts, et al. Immuno-Hematological and Biochemical Changes in Patients with Tuberculosis in Dessie Comprehensive Specialized Hospital, Dessie, Ethiopia. *Journal of Blood Medicine* [Internet]. 2024 Mar 1 [cited 2024 Oct 9];Volume 15:147–55. Available from: <https://www.dovepress.com/immuno-hematological-and-biochemical-changes-in-patients-with-tubercul-peer-reviewed-fulltext-article-JBM>
- [5] Şahin F, Yazar E, Yıldız P. Prominent features of platelet count, plateletcrit, mean platelet volume and platelet distribution width in pulmonary tuberculosis. *Multidisciplinary respiratory medicine*. 2012 Dec;7:1-7.
- [6] Lee MY, Kim YJ, Lee HJ, Cho SY, Park TS. Mean platelet volume in *Mycobacterium tuberculosis* infection. *BioMed Research International*. 2016;2016(1):7508763.
- [7] Kutiya AS, Gupta N, Garg S, Hira HS. A study of haematological and haemostasis parameters and hypercoagulable state in tuberculosis patients in northern India and the outcome with anti-tubercular therapy. *Journal of clinical and diagnostic research: JCDR*. 2017 Feb;11(2):OC09.
- [8] Kirwan DE, Chong DL, Friedland JS. Platelet activation and the immune response to tuberculosis. *Frontiers in Immunology*. 2021 May 19;12:631696.
- [9] Fox K, Kirwan DE, Whittington A, Krishnan N, Gilman RH, López JW, et al. Platelets Regulate Pulmonary Inflammation and Tissue Destruction in Tuberculosis. *American Journal of Respiratory and Critical Care Medicine*. 2018 Jul 15;198(2):245–55.
- [10] Cox DJ, Keane J. Platelets and Tuberculosis: Small Cells, Not So Innocent Bystanders. *American Journal of Respiratory and Critical Care Medicine*. 2018 Jul 15;198(2):153–4.
- [11] Mwilita, E., Kimoloi, S., & Raballah, E. (2024). Hematological profiles of newly diagnosed pulmonary tuberculosis patients in Western Kenya. *International Journal Of Community Medicine And Public Health*, 11(6), 2225–2233. <https://doi.org/10.18203/2394-6040.ijcmph20241480>
- [12] Mani S, Karampudi D. Reactive Thrombocytosis in Tuberculosis [Internet]. [cited 2024 Oct 9]. Available from: <https://jcdronline.org/admin/Uploads/Files/65259182d98b51.56439559.pdf>
- [13] Shah AR, Desai KN, Maru AM. Evaluation of hematological parameters in pulmonary tuberculosis patients. *Journal of family medicine and primary care*. 2022 Aug 1;11(8):4424-8.
- [14] Garg B. Reactive thrombocytosis-etiology and its relationship with different hematological parameters, ESR, & CRP in Tuberculosis. *Inflammation (non-tuberculosis)*.;47:9-4.
- [15] Angesom Gebreweld, Temesgen Fiseha, Kebede E, Tamir Z, Gebremariam B, Fikadu Miruts, et al. Immuno-Hematological and Biochemical Changes in Patients with Tuberculosis in Dessie Comprehensive Specialized Hospital, Dessie, Ethiopia. *Journal of Blood Medicine* [Internet]. 2024 Mar 1;Volume 15:147–55. Available from: <https://www.dovepress.com/immuno-hematological-and-biochemical-changes-in-patients-with-tubercul-peer-reviewed-fulltext-article-JBM>
- [16] Maru A, Shah A, Desai K. Evaluation of hematological parameters in pulmonary tuberculosis patients. *Journal of Family Medicine and Primary Care*. 2022;11(8):4424.
- [17] Masooma Jaffer, Omar Shahid, Ramaisha Aslam, Fatima Saeed, Atiqa Arshad, Muhammad Touqeer Hanif. Frequency of different causes of thrombocytosis among patients presenting to tertiary care hospital. *The Professional Medical Journal* [Internet]. 2024 Apr 1 [cited 2024 Oct 9];31(04):581–7. Available from: <https://theprofesional.com/index.php/tpmj/article/view/7981>
- [18] Batool Y, Pervaiz G, Arooj A, Fatima S. Hematological manifestations in patients newly diagnosed with pulmonary tuberculosis. *Pakistan Journal of Medical Sciences*. 2022 Sep;38(7):1968.
- [19] Kumarihamy K, Ralapanawa D, Jayalath W. A rare complication of pulmonary tuberculosis: a case report. *BMC Research Notes* [Internet]. 2015;8(1):39. Available from: <https://www.ncbi.nlm.nih.gov/pmc/articles/PMC4328059/>
- [20] Mckinnon A, Madua M. Pulmonary tuberculosis as a contemporary risk factor for pulmonary embolism. *Case Report 1 African Journal of Respiratory Medicine* [Internet]. 2024 [cited 2024

- Oct 9];19. Available from:
<https://www.africanjournalofrespiratorymedicine.com/articles/pulmonary-tuberculosis-as-a-contemporary-risk-factor-for-pulmonary-embolism.pdf>
- [21] Lee MR, Lee MC, Chang CH, Liu CJ, Chang LY, Zhang JF, et al. Use of Antiplatelet Agents and Survival of Tuberculosis Patients: A Population-Based Cohort Study. *Journal of Clinical Medicine* [Internet]. 2019 Jun 27 [cited 2024 Oct 9];8(7):923–3. Available from: <https://www.mdpi.com/2077-0383/8/7/923>.